

## Cases of teeth concrescence in the Pacific walrus (*Odobenus rosmarus divergens*)

Natalia V. Kryukova

**ABSTRACT.** Three cases of concrescence of the fourth premolar with the first molar and one case of concrescence of the third and the fourth premolars are described in the Pacific walrus, *Odobenus rosmarus divergens* (Illiger, 1815). These cases represent 0.3% of the total number of inspected teeth ( $n = 1206$ ) from 307 animals. All individuals ( $n = 3$ ) were adult males aged 22–26 years old. The beginning of concrescence was found in animals ranging from 7 to 23 years old. The sections of concrescent teeth showed them to be joined by newly deposited layers of cementum.

How to cite this article: Kryukova N.V. 2017. Cases of teeth concrescence in the Pacific walrus (*Odobenus rosmarus divergens*) // Russian J. Theriol. Vol.16. No.1. P.110–113. doi: 10.15298/rusjtheriol.16.1.10

**KEY WORDS:** dental anomalies, concrescence, Pacific walrus.

Natalia V. Kryukova [nkryukova@gmail.com], Russian Federal Research Institute of Fisheries and Oceanography (VNIRO), 17, Verkhnyaya Krasnosel'skaya Street, 107140 Moscow, Russia.

## Случаи срастания зубов у тихоокеанского моржа (*Odobenus rosmarus divergens*)

Н.В. Крюкова

**РЕЗЮМЕ.** Описываются три случая срастания четвертого премоляра и первого моляра и один случай срастания третьего и четвертого премоляров у трех взрослых особей тихоокеанского моржа, *Odobenus rosmarus divergens* (Illiger, 1815). Эти случаи составили 0,3% от общего количества обследованных зубов ( $n = 1206$ ) от 307 животных. Все особи ( $n = 3$ ) были взрослые самцы в возрасте 22–26 лет. Срастание зубов началось, когда возраст животных был от 7 до 23 лет. Срезы сросшихся зубов показали, что они соединились при помощи новых слоев цемента.

**КЛЮЧЕВЫЕ СЛОВА:** зубные аномалии, срастание зубов, тихоокеанский морж.

### Introduction

Dental anomalies occasionally occur in the development of mammals. One of these aberrations is represented by joining of teeth. The frequency of occurrence of this abnormality is less than 1% (Drehmer *et al.*, 2015; Neville *et al.*, 2016). There are a few published descriptions of joined teeth in marine mammals (Lönnberg, 1922; Miles & Grigson, 1990; Drehmer *et al.*, 2004, 2015; Winer *et al.*, 2016.). By far the most complete data on this anomaly have been collected in humans, including detailed descriptions of various manifestations of joined teeth (Neville *et al.*, 2016).

In the literature, four terms concerning joined tooth are frequently described: double tooth, fusion, gemination, and concrescence. Some of these terms occasionally overlap, and in some situations cases with similar etiology have been given different names. This reflects the difficulties inherent in distinguishing different types of joined teeth using only external characters. In each case additional investigation is required (Gunduz *et al.*, 2006) to determine the specific type of join. These types are “fusion” or “concrecence”. The fusion is defined as a single enlarged tooth or joined (double) tooth in a dentition where the tooth count reveals a

missing tooth when the anomalous tooth is counted as one. The concrescence is a union of two adjacent teeth by cementum only, without confluence of underlying dentin (Neville *et al.*, 2016).

We found only one published description of such a case in the walrus, *Odobenus rosmarus divergens* (Illiger, 1815), involving fusion of the right mandibular fourth premolar tooth with the adjacent first molar tooth (Winer *et al.*, 2016). We encountered several similar cases during the field season of 2011 in Chukchi Sea, Russia (personal collection of the author). The aim of this work was to identify the type of teeth union, and to investigate and describe in detail these rare cases.

### Material and Methods

Maxillae and/or mandibles from dead and harvested walruses were examined in three areas: Retkyn Spit (Bering Sea) in 2007 and 2008, Vankarem Cape, Kolyuchin Island, and the area of the Chegitun River (Chukchi Sea) in 2010 and 2011. In addition, maxillae and/or mandibles of the Pacific walrus from several museums (Zoological Museum of Moscow University, Zoological Institute of the Russian Academy of Sciences, Museum of the Russian Federal Research Institute of Fish-

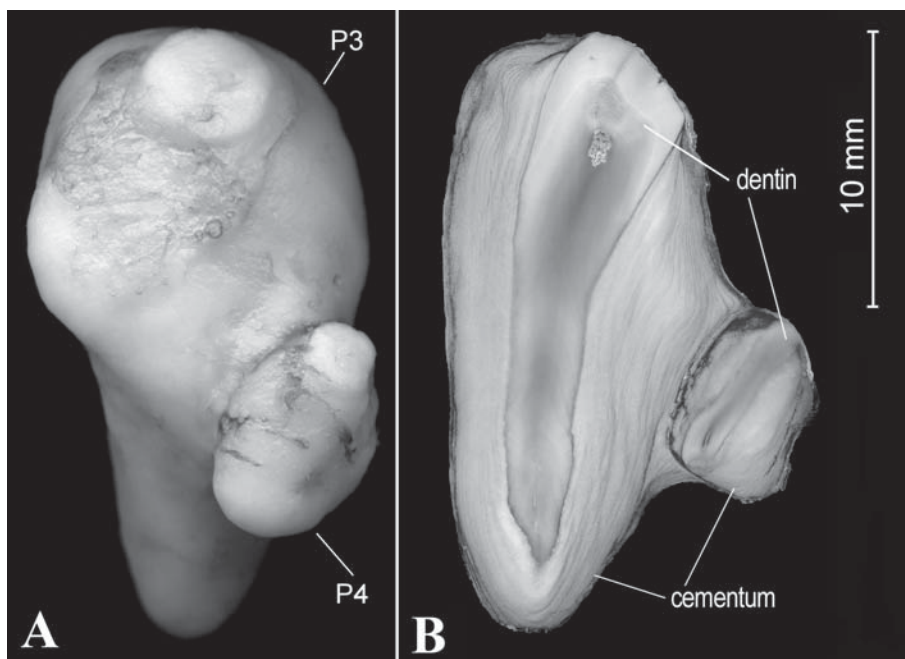


Fig. 1. Pacific walrus (*O. rosmarus divergens*), Vankarem Cape, Chukotka, Russia (personal collection of the author), male 24 years old. Concrescence of left maxillary third premolar (P3) with the adjacent fourth premolar (P4) in the 2nd individual (A — photo, B — section).

eries and Oceanography) and a personal collection were examined. A total of 1206 teeth from 307 walruses, including 274 teeth from 54 calves of the year, were examined.

Joined teeth were extracted from jaws and then separated from tissue remains. Using calipers, measurements were taken of the total tooth length and maximum width to an accuracy of 0.5 mm. Sections of 50–55  $\mu\text{m}$  (micrometer) width were prepared from the core part of each tooth using a low-speed saw with diamond coating (Buehler Isomet). All sections were scanned using an Epson Perfection V700 Photo flatbed scanner to obtain high-resolution images (4000 dpi), necessary for the better view of cement layers. The cement and dentine layers were counted (using tools of a contrast and sharpness) in images of the teeth using Adobe Photoshop CS3 Software. The method of age determination of walrus using the layered structure of teeth has been known for a long time (Klevezal' & Kleinenberg, 1967). Age determination of walruses is based on counting cement layers deposited on a tooth root. A single cement layer consists of one light line and one dark line and corresponds one year of life (Mansfield, 1958). A more detailed account on the preparation of sections and age determination is given in our earlier study (Kryukova, 2014).

## Results and discussion

In the examined material ( $n = 1206$ ), joined teeth were detected in only four cases in three adult walruses,

from the Vankarem Cape region (Chukchi Sea). In one individual (1st male, age 26 years), both rudimentary (vestigial) teeth were joined in the maxilla: fourth premolar and first molar (Fig. 2). In the remaining cases, there was a union of a functional tooth with a rudimentary tooth: in one individual (2nd male, age 24 years) this occurred in the maxilla between the maxillary third premolar and fourth premolar (Fig. 1), and in another individual (3rd male, age 22 years) in the mandible between the mandibular fourth premolar and the first molar (Fig. 3).

Teeth dimensions were measured as following: maxillary third premolar (total tooth length is 2.4 cm; maximum width, 1.25 cm), maxillary fourth premolar,  $n = 3$ , (total tooth length, 0.85–1.55 cm; maximum width, 1.25–1.5 cm), maxillary first molar,  $n = 2$ , (total tooth length, 0.5–0.7 cm; maximum width, 0.5–0.55 cm), mandibular fourth premolar (total tooth length, 3.4 cm; maximum width, 2 cm), mandibular first molar (total tooth length, 1 cm; maximum width, 0.6 cm).

In all four pairs of joined teeth, one tooth was smaller than the other. The area of union of the teeth was along the root surfaces and was effected by cementum. In one pair, the smaller tooth joined the larger tooth at the middle; in the other three pairs the small tooth joined with the upper part of the large tooth, near the attrition surface (the crown) of the tooth.

The union of teeth by cementum which occurred without the union of dentin is shown in Figure 1. According to the classification described by Neville *et al.* (2016), this is a concrescence type of joined teeth. Prior

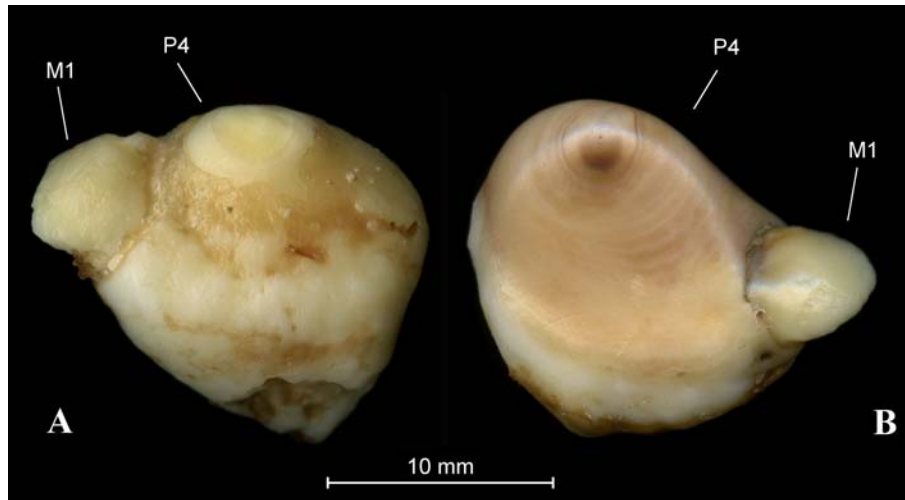


Fig. 2. Pacific walrus (*O. rosmarus divergens*), Vankarem Cape, Chukotka, Russia (personal collection of the author), male 26 years old. Concrescence of the maxillary fourth premolar (P4) with the adjacent first molar (M1) in the 1st individual (A — right side; B — left side).

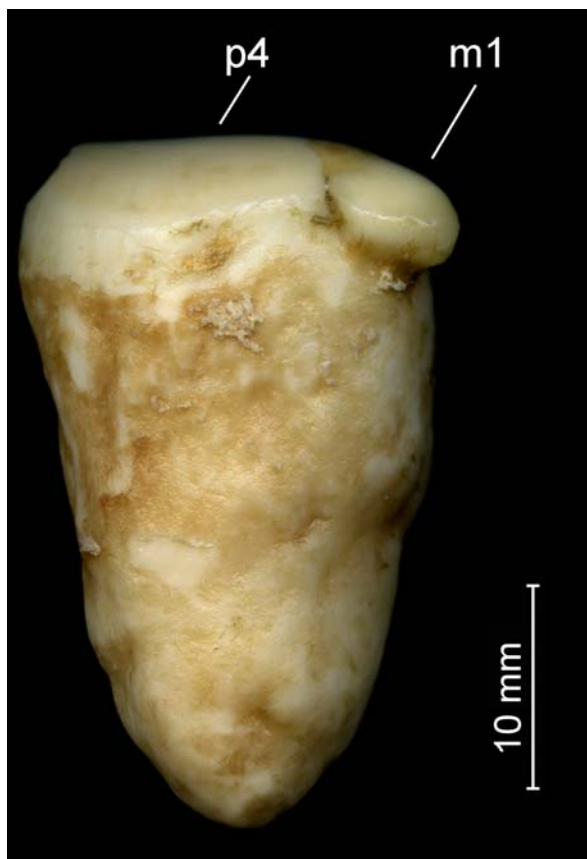


Fig. 3. Pacific walrus (*O. rosmarus divergens*), Vankarem Cape, Chukotka, Russia (personal collection of the author), male 22 years old. Concrescence of the right mandibular fourth premolar (p4) with the adjacent first molar (m1) in the 3rd individual.

to the concrescence of teeth, normal annual cement layers were deposited around the root surface of each tooth. When concrescence begins, the annual cement layers join the root area of both teeth. At the same time new layers were not formed in the contact area between the two teeth. As a result, in the root area of joined teeth, we found a higher number of annual cement layers than in the same teeth along the contact area. Our results show that the age of the beginning of teeth concrescence in the 1st animal was 11 years (1st pair of teeth) and 20–23 years (2nd pair of teeth). In the 2nd animal, concrescence occurred at 12 years, and at 7 years in the 3rd animal. In some teeth the cement on external surface of root was partly resorbed. This occurred in both pairs of the rudimentary teeth of the 1st individual, and in the first molar of the 3rd individual.

There are several factors potentially affecting this process as a tooth pair developing in close proximity, local trauma, systemic disease, lack of vitamins, and genetics (Knežević *et al.*, 2002; Gunduz *et al.*, 2006). Trauma or disease could partly destroy the cement of the tooth, and subsequent repair of the damaged area by cement layers could lead to teeth union, especially if an adjacent tooth is close (Neville *et al.*, 2016).

In our study it was shown that teeth are joined by newly deposited layers of cementum. The particular causes of the described cases of teeth concrescence are unclear and need more investigations.

**ACKNOWLEDGEMENTS.** The author thanks the Laboratory of Postnatal Ontogenesis, Institute of Developmental Biology, Russian Academy of Sciences and G.A. Klevezal' for the research opportunity. The author is also grateful to D.D. Vasyukov (A.N. Severtsov Institute of Ecology and Evolution, Russian Academy of Sciences) for samples collected near the Chegitun River and G. Sheffield for samples collected near

Nome, Alaska. I am sincerely grateful to the anonymous reviewer and to Prof. Frank J.M. Verstraete for their valuable comments to the manuscript.

## References

- Drehmer C.J., Fabian M.E. & Menegheti J.O. 2004. Dental anomalies in the Atlantic population of South American Sea Lion, *Otaria Byronia* (Pinnipedia, Otariidae): evolutionary implications and ecological approach // Latin American Journal of Aquatic Mammals. Vol.3. No.1. P.7–18.
- Drehmer C.J., Sanfelice D. & Loch C. 2015. Dental anomalies in pinnipeds (Carnivora: Otariidae and Phocidae): occurrence and evolutionary implications // Zoomorphology. Vol.134. No.2. P.325–338.
- Gunduz K., Sumer M., Sumer A. P. & Gunhan O. 2006. Concrescence of a mandibular third molar and a supernumerary fourth molar: Report of a rare case // British Dental Journal. Vol.200. No.3. P.141–142.
- Klevezal' G.A. & Kleinenberg S.E. 1967. [Age determination of mammals by layered structure of teeth and bone]. Moscow: Nauka. 144 p. [in Russian].
- Knežević A., Travan S., Tarle Z., Šutalo J., Janković B. & Ciglar I. 2002. Double tooth // Collegium Antropologicum. Vol.26. No.2. P.667–672.
- Kryukova N.V. 2014. The method of age determination of the Pacific Walrus (*Odobenus rosmarus divergens*) using the layered structure of functional teeth // Biology Bulletin. Vol.41. No.8. P.681–689.
- Lönnerberg E. 1922. On some anomalies in the dentition of *Phoca hispida* // Bijdragen tot de Dierkunde. Vol.22. No.1. P.169–173.
- Mansfield A.W. 1958. The biology of the Atlantic walrus, *Odobenus rosmarus rosmarus* (Linnaeus) in the eastern Canadian Arctic // Fisheries Research Board of Canada Manuscript Report Series (Biology). No.653. 146 p.
- Miles A.E.W. & Grigson C. 1990. Colyer's variations and diseases of the teeth of animals. Revised edition. Cambridge: Cambridge University Press. 676 pp.
- Neville B.W., Damm D.D., Allen C.M. & Chi A.C. 2016. Abnormalities of teeth // Oral and Maxillofacial Pathology. Fourth edition. Canada: Elsevier, St. Louis. P.49–110.
- Winer J.N., Arzi B., Leale D.M., Kass P.H. & Verstraete F.J.M. 2016. Dental and temporomandibular joint pathology of the walrus (*Odobenus rosmarus*) // Journal of Comparative Pathology. Vol.155. No.2–3. P.242–253.